

Paediatric Ameloblastomas in Mandible: Two Case Reports with Pathogenesis and Literature Review

Mounabati Mohapatra*, Banushree C.S.**

Abstract

Ameloblastomas are enigmatic group of oral tumors. The name implies a resemblance to cells of the enamel-forming organ. The tumor is often asymptomatic, presenting as a slowly enlarging facial swelling or an incidental finding on a radiograph. The tumor is considered a rarity in the young, but the tumor grows slowly and probably starts to develop in childhood. The treatment of ameloblastoma presents some special problems in children, growth of the jaw, different incidence, behavior, and prognosis of the tumor in children make the surgical consideration different from adults. However, only a few articles discuss ameloblastomas in children and adolescents. Considering the rarity of the lesion, we report here an interesting and unique case of unicystic and solid ameloblastoma of the mandible occurring in a 11 year old boy and 12 year old boy respectively with review of literature of Pathogenesis in children.

Keyword: Unicystic; Solid Ameloblastoma; Plexiform; Mandible; Paediatric Age.

Introduction

According to the WHO 1992 definition, ameloblastoma is a benign but locally invasive polymorphic neoplasm consisting of proliferating odontogenic epithelium, which usually has a follicular or plexiform pattern, lying in a fibrous stroma [1]. In 1977, Robinson and Martinez first contributed the term 'unicystic ameloblastoma' [2].

WHO histological typing of odontogenic tumours classifies ameloblastoma as intra-osseous central, and extra-osseous peripheral types, the small number of ameloblastomas arising directly from the surface epithelium or from residues of the dental lamina lying outside the bone constitute the peripheral type [1]. This tumor is most commonly seen in molar and ramus area of the mandibular jaw bone of individuals in 3rd to 4th decade of life [3]. The unicystic ameloblastoma, a variant of ameloblastoma, has been reported to occur in decade earlier than its solid counterpart [4]. The unicystic ameloblastoma, a

variant of ameloblastoma, first described by Robinson and Martinez in 1977, is reported to have a less aggressive biologic behavior and lower recurrence rate than the classic solid or multicystic ameloblastoma [2]. Here the treatment involves either simple enucleation or excision. We are presenting a case report of one such rarity where plexiform unicystic ameloblastoma showing mural proliferation, in an otherwise healthy eleven year old boy involving ramus of the mandible and solid unilocular plexiform ameloblastoma in a twelve year old boy.

Case report I

A 12 year-old boy residing in a tribal area of Odisha reported to Department of dental surgery, with a complaint of pain & swelling on the right side of face since past 2 years & difficulty in chewing, eating for the same reason. Extra oral examination revealed a diffuse swelling on right side of face, which on palpation was firm & non tender & of size 11 x 10 cm arising from the lower jaw extending superiorly from zygomatic arch, inferiorly up to the sub-mandibular region, anteriorly from angle of mouth, posteriorly up to the angle of mandible & tragus of ear (figure 1a). Intra orally there was obliteration of buccal sulcus with a soft tissue extension of size 4 x 5 cm from tooth 42 to retromolar area. Lingually the mass was present

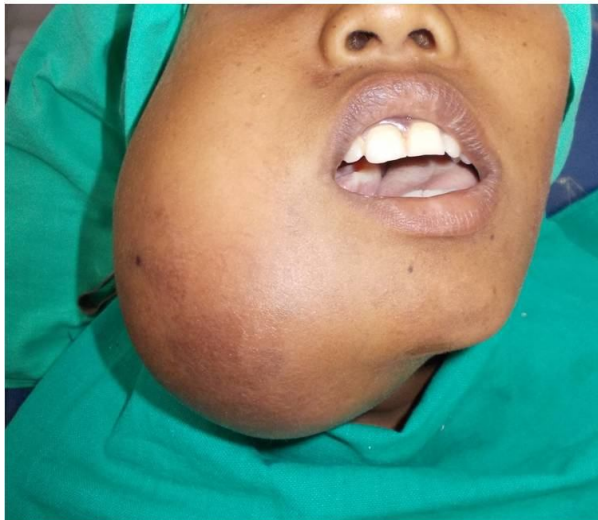Author's Affiliation: **Professor and HOD, Departments of Oral and Maxillofacial surgery ** Professor, Departments of Pathology, AIIMS, Bhubaneswar.

Reprints Requests: Mounabati Mohapatra, Professor and HOD, Dept. of Dental Surgery, Maharaja Krushna Chandra Gajapati Medical College & Hospital, Berhampur, Ganjam Odisha- 760004.
E-mail: mounabatimohapatra@gmail.com

in the floor of the mouth & pushing the tongue to opposite side. Both deciduous & permanent teeth present in the involved alveolus are found to be disoriented & mobile. On palpation, the swelling was firm and nontender. A lymph node identified in the sub-mandibular region measuring 20x10x10mm. Fine needle aspiration cytology of lymph node showed features of reactive hyperplasia of lymph node. His physical examination revealed no abnormality other than the chief complaint.

Radiography lateral oblique X-ray revealed a unilocular radiolucency extending from anterior ramus up to condyles & sigmoid of mandible with an impacted tooth inside. Enhancing mass measuring 10 x 11 cm right mandibular ramus. Lesion is expansile causing thinning of the right mandible.

Fig. 1 a: (right hand side) showing diffuse swelling on right side of the face measuring 11x10cm



Case report II

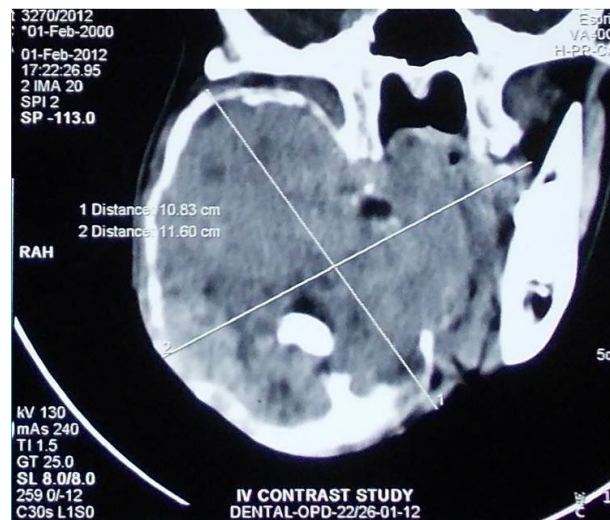
An eleven year-old boy residing in a rural area of odisha reported to Department of dental surgery, with a complaints of slow growing, painless swelling on the left side of face since one year and gives history of extraction of teeth 37 six months back due to mobility. Extra oral examination revealed a diffuse swelling on left side lower third of face, which on palpation was firm and non tender and of size 7x 6 cm arising from the lower jaw. Intra orally there was firm swelling extending from 36 to anterior border of ramus along with lingual cortical plate expansion and an exophytic growth at the socket of 37 (figure 2a). A lymph node identified in the sub-mandibular region measuring 25 x 10 x 10 mm. His physical examination revealed no abnormality other than the chief complaint.

Left mandible appears normal. CT showed an expansile osteolytic lesion of 11 x 10 cm size involving the whole of right side mandible with tooth inside (figure 1b).

Patient found to be anemic with Hb- 6.8%. Blood picture reveals dimorphic anemia with adequate platelet concentration. Past medical history was irrelevant. He was taking no medication & had no history of known drug allergy.

Provisional diagnosis was odontogenic tumour. After a blood transfusion, incisional biopsy was done & sent for final diagnosis. Histopathology revealed anastomosing strands and thin trabeculae lined by basal cells separated by thin fibrous stroma. No evidence of pleomorphism or mitosis identified. Final diagnosis of plexiform ameloblastoma was made.

Fig. 1 b: (left hand side) CT image showing expansile osteolytic lesion of 11 x 10 cm size involving the whole of right side mandible with tooth inside



Radiography revealed expansile-lytic lesion involving the left ramus and angle of the mandible extending upto the first molar (36) at its antero-inferior part (figure 2b). The lesion appears uniformly lytic without any sclerotic focus/septae and fine needle aspiration was planned.

Straw colored fluid was aspirated and sent for cytological examination. Fine needle aspiration of the swelling showed few scattered squamous epithelial cells, cyst macrophage in a proteinaceous background. Suggestive of Benign cystic lesion of jaw. Histopathology revealed anastomosing strands and thin trabeculae lined by basal cells enclosing stellate reticulum showing extensive cystic change surrounded by thin fibrous stroma. Features suggested cystic plexiform ameloblastoma (figure 3a & b). In view of radiological and morphological findings, final diagnosis of Unicystic plexiform Ameloblastoma was made.

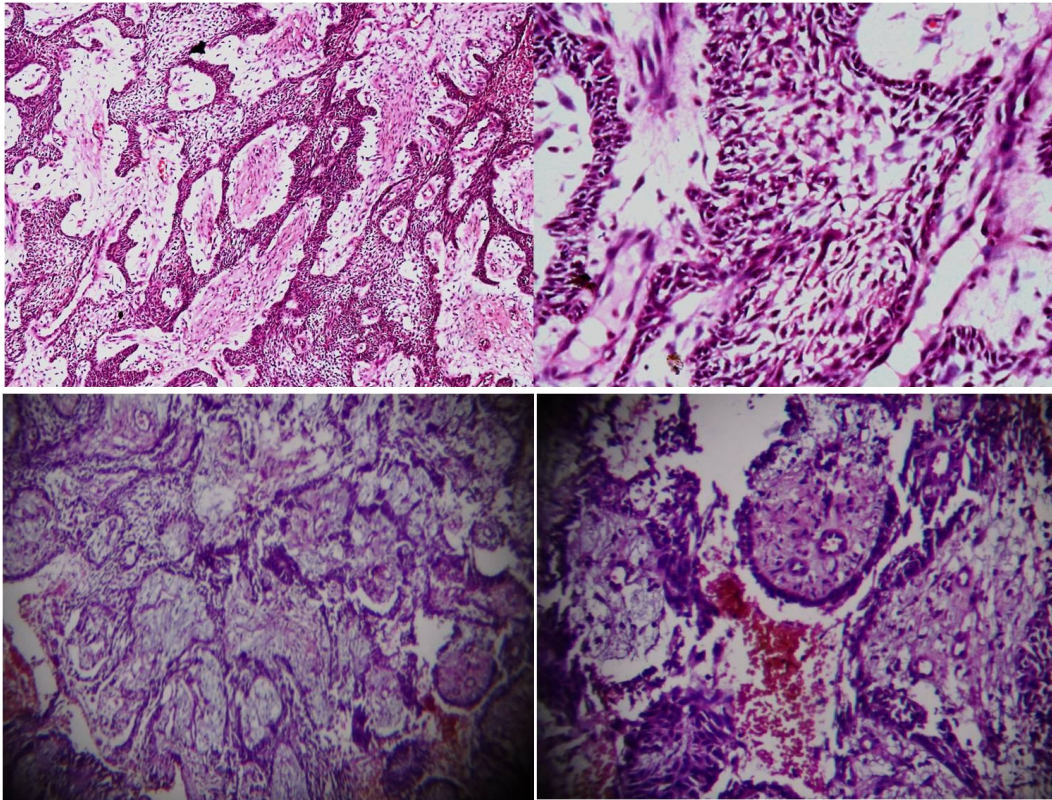
Fig. 2 a: (right hand side) photograph showing intra-oral firm swelling extending from 36 to anterior border of ramus along with lingual cortical plate expansion. Exophytic growth at the socket of 37

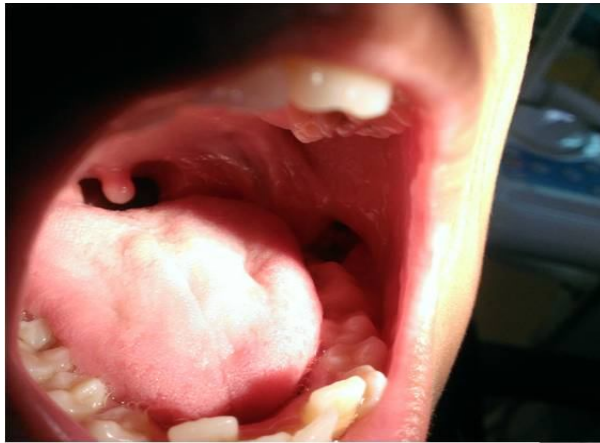

Fig. 2 b: (left hand side) Radiograph showing expansile-lytic lesion involving the left ramus and angle of the mandible extending upto the first molar (36) at its antero-inferior part

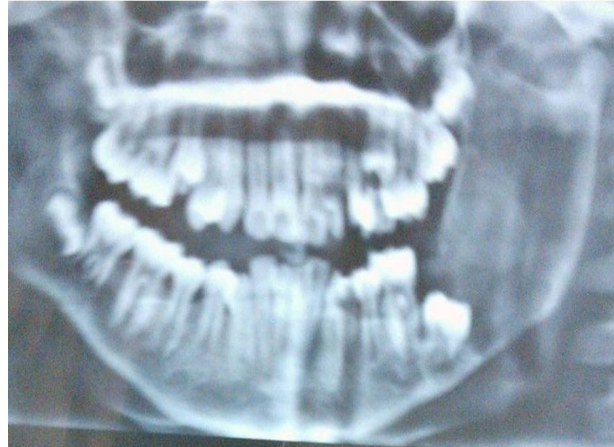

Fig. 3 a & b: (H&E, 10x & 40x magnification) Photomicrograph showing anastomosing strands and thin trabeculae lined by basal cells separated by thin fibrous stroma



Treatment

Unfortunately we could not provide any treatment for both patients as the arents were unwilling for resection of jaw.

Discussion

Ameloblastoma occur in three different clinico-radiographic situations namely, Conventional solid/

multicystic, Unicystic and Peripheral [4]. Odontogenic tumors in children are known to have predilection for the mandible. This is also corroborated by our findings with both the tumors occurring in the mandible. Al-Khateeb et al however found 64% of cases in maxilla [5].

Ackerman et al, in their study of unicystic ameloblastomas, defined three subgroups.

Group I (42%) consisted of a unilocular cyst with a nondescript but variable epithelial lining. Inactive

odontogenic cell rests might be present in the fibrous wall, but there was no infiltration by neoplastic epithelium.

Group II lesions (9%) featured intraluminal plexiform proliferation but no infiltration of the cyst wall.

Group III lesions (49%), plexiform or follicular — type ameloblastoma, sometimes in continuity with the cyst lining, infiltrated the wall. These lesions need to be treated more aggressively similar to solid/multicystic Ameloblastoma [4,6].

Ameloblastoma is uncommon in children. Several extensive surveys and reviews of ameloblastoma have been published, the most notable being those of Robinson in 1937 and Small and Waldron in 1955. Analysis of more than 1,000 cases by the authors revealed that the ameloblastoma most commonly occurs in the 20 to 49 years age, with average age at first diagnosis being about 39 years but only 2.2% under 10 years of age and 8.7% between 10 and 19 years of age [7]. The mean age was 41.4 years for solid ameloblastoma and 26.3 years for unicystic ameloblastoma and both sexes were almost equally affected. The mandible was mainly affected in both Unicystic and Solid Ameloblastoma. The mean size was 6.2 cm for Solid and 6.3 cm for unicystic cases. The recurrence rate is 21.7% for Solid and 12.6% for Unicystic. Unicystic is twice as more frequent than the solid variant [8].

The solid/multicystic ameloblastoma is a slowly growing locally invasive, epithelial odontogenic tumour of the jaws with a high rate of recurrence if not removed adequately, but with virtually no tendency to metastasize. Tumour is rare below the age of 20 years. There are two basic histopathologic patterns, the follicular and plexiform, without clinical relevance. Long-term follow-up is essential, since recurrences have been noted more than 10 years after the initial treatment [9].

Molecular studies have offered interesting findings regarding ameloblastoma pathogenesis. It is clear from the literature reviewed that translational studies are necessary to identify prognostic markers of ameloblastoma behaviour and to establish new diagnostic tools to the differential diagnosis of unicystic from multicystic ameloblastoma [10].

Conclusion

The present case reports of a twelve year old boy with solid plexiform ameloblastoma and eleven year old boy with unicystic ameloblastoma with

extensive plexiform mural proliferation, occurring in mandibular ramus region, is rare and unique in its age of occurrence and size. This cases adds to the very few paediatric cases reported in literature, where plexiform unicystic ameloblastoma with extensive mural proliferation histopathologically and reaching a size of 7 cm X 6 cm and solid ameloblastoma reaching a size of 11 x 10 cm as evidenced clinically and radiographically in just twelve and eleven year old child respectively. This huge size within a small time period could be because of the growth period of jaw in this young boys. More such cases should provide us an insight into the biologic behaviour and clinical course of this tumor which may help in effective treatment plan.

References

1. Gulden, Vedat , Hilal. Unicystic Ameloblastoma in 8 Years old Child: A Case Report Review of Unicystic Ameloblastoma. *international dental & medical disorders* 2008; 1(1): 29-33.
2. Robinson L, Martinez MG. Unicystic ameloblastoma: a prognostically distinct entity. *Cancer* 1977; 40: 2278–85.
3. Seintou A, Martinelli-Klay CP, Lombardi T. Unicystic ameloblastoma in children: systematic review of clinicopathological features and treatment outcomes. *Int J oral maxillofac Surg* 2014; 43: 405-412.
4. Roderick A Cawson, William H. Binnie, Paul M. Speight, Andrew W. Barret, John M Wright . From Ch. Odontogenic tumors . *Lucas's Pathology of tumors of the Oral tissues*. 5th Edition, Churchill Livingstone, 1998; Pg. 25.
5. Al- Khateeb T, Hamasha AA, Almasri NM: Oral and maxillofacial tumours in North Jordanian children and adolescent: a retrospective analysis over 10 years. *Int J Oral Maxillofac Surg* 2003; 32: 78-83.
6. Ackermann GL, Altini M, Shear M. the unicystic ameloblastoma: a clinico pathologic study of 57 cases. *J. Oral pathol* 1988; 17: 541-546
7. Robert J, Gorlin D.D.S, Anand P, Chaudhry , Jens J, Pindborg et al. Odontogenic Tumors. *Cancer* 1961; 14: 73- 101.
8. Chedesma-montes, A Mosqueda-Taylor, R Carlos-Bregni, E Romeo De Leon et al. Ameloblastoma: a regional Latin-American multicentric study 2007; 13: 303-307.

9. Gardner DG, Heikinheimo K, M. Shear, H.P. Philip Sen, H. Coleman. From Ch Ameloblastomas. WHO pathology and genetics of head and neck tumours. 2005; pg 296-297.
10. Carolina Cavaliere Gomes, Alessandra Pires Duarte, Marina Goncalves Diniz, Ricardo Santiago Gomez. Current concepts of ameloblastoma pathogenesis. *J Oral Pathol Med.* 2010; 39: 585-591.
-

*Introducing a new sister concerned company of **Red Flower Publication Pvt. Ltd.***

RF Library Services Pvt. Ltd.

RF Library Services Pvt. Ltd. is a global market leader in managing professional information. We develop and deliver innovative services that enable the use of knowledge to its full extent. As the only information Service Company globally we play a key role in today's complex information marketplace. Founded in 1985 as a registered company under sub-section (2) of section 7 of the Companies Act, 2013 and rule 8 of the Companies (Incorporation) Rules, 2014, the business draws on more than a decade of experience within the information industry. With this knowledge, we satisfy the needs of thousands of customers from over 30 countries. We are a division of Red Flower Publication Pvt. Ltd.

Where we are based?

RF Library Services Pvt. Ltd is located in Delhi-91 in India.

RF Library Services Pvt. Ltd.

D-223/216, Laxmi Chambers, Laxmi Nagar,
Near Laxmi Nagar Metro Station,
Delhi-110092(India)

Tel: 011-22756995, Fax: 011-22756995

E-mail: rflibraryservices@vsnl.net, rflibraryservices@gmail.com

Website: www.rf-libraryservices.com